

# Treatment of Lower Eyelid Fat Pads Using Phosphatidylcholine: Clinical Trial and Review

GYNIS ABLON, MD,<sup>n</sup> AND ADAM M. ROTUNDA, MD<sup>w</sup>

<sup>n</sup>West Los Angeles Veteran Administration Medical Center, and<sup>w</sup>Division of Dermatology, David Geffen School of Medicine, University of California at Los Angeles, Los Angeles, California

**BACKGROUND.** Injectable phosphatidylcholine, a lecithin-derived phospholipid, has been previously demonstrated to improve the appearance of infraorbital fat pad herniation. Current use internationally has led to a significant interest in this novel substance.

**OBJECTIVE.** To evaluate the efficacy and safety of injectable phosphatidylcholine, we conducted an open-label study for the treatment of infraorbital fat pad herniation.

**METHODS.** Patients received 0.4-mL phosphatidylcholine (50 mg/mL) injections within infraorbital fat pads every 2 weeks. Patient and physician grading of fat herniation, side effects, digital photographs, and a follow-up questionnaire was recorded.

**RESULTS.** Ten of the 13 enrolled patients had three to five treatments. Improvements in fat herniation were reported in

80% and 70% of patients as graded by the physician and patients, respectively. Sixty percent of patients assessed their improvement as equal or greater than 5 points (on a 10-point fat herniation scale); however, the physician judged 40% of patients improving to this degree. Little or no response was seen in three patients. Side effects included burning, erythema, and swelling at the injection site. At follow-up averaging 9 months, 50% of patients reported persistence of benefit 20% experienced some fading, and 30% were the nonresponders.

**CONCLUSIONS.** Injectable phosphatidylcholine is a novel treatment for infraorbital fat herniation that may benefit some patients who are considering blepharoplasty. Larger studies evaluating long-term safety and efficacy of phosphatidylcholine for cosmetic purposes are warranted.

G. ABLON, MD, AND A. M. ROTUNDA, MD HAVE INDICATED NO SIGNIFICANT INTEREST WITH COMMERCIAL SUPPORTERS.

BAGGY, PUFFY EYELIDS are viewed by most people as a sign of exhaustion and aging. Many individuals will go to great lengths to improve the appearance of their periorbital skin using cosmetics, fillers, botulinum toxin, chemical peels, dermabrasion, lasers, and surgical procedures. In 2002, nearly 230,000 people in the United States had a blepharoplasty, the fourth most popular surgical cosmetic procedure, as a method to attain a more desirable appearance.<sup>1</sup> However, patients desire similarly effective yet less invasive solutions with faster recovery times.

Baggy eyelids result from periorbital fat herniation, excessive eyelid skin (blepharochalasis), and/or hypertrophied orbicularis muscle.<sup>2</sup> Baggy infraorbital folds caused by herniation of infraorbital fat pads are anatomically defined as true herniation of one or more of the three lower lid fat pads between the capsulopalpebral ligament superiorly and the orbital septum inferiorly. These must be clinically differentiated from

other causes of periorbital edema, including eczema, conjunctivitis, urticaria, angioedema, arthropod bites, trauma, sinusitis and uncommonly, rosacea, dermatomyositis, thyroid disease, amyloidosis, hypoproteinaemia, hypervolemia, and lymphoma, among others.<sup>3,4</sup>

Rittes<sup>5</sup> was the first to demonstrate cosmetic improvement of bulging infraorbital skin using injectable phosphatidylcholine, a phospholipid derived from lecithin. A recent report by Hexsel et al.<sup>6</sup> describes the use of phosphatidylcholine injections for cosmetic applications in 213 patients, 8 of whom had HIV lipodystrophy. In an effort to evaluate further the efficacy and safety of phosphatidylcholine injections and to provide a nonsurgical alternative for our patients, we conducted an open-label study for the treatment of localized infraorbital fat pads.

## Methods

This study was approved by the appropriate institutional review boards and conformed to the ethical guidelines of the 1975 Declaration of Helsinki. Written informed consent was obtained from each patient.

Address correspondence and reprint requests to: Glynis Ablon, MD, Ablon Institute for Dermatology and Laser Rejuvenation, Raleigh Studios, 1600 Rosencrans Avenue, 6A, #12, Manhattan Beach, CA 90266, or e-mail: glynisandsteve@aol.com.

In order to participate in the study, patients had to be greater than 25 years of age and be in good health with no other skin diseases. Exclusion criteria included a history of sensitivity to phosphatidylcholine, previous blepharoplasty, involvement in other clinical investigations concurrently or within the previous 4 weeks, a known bleeding disorder or concomitant use of anticoagulants, pregnancy, use of systemic retinoids during the past 6 months or during the study (except 12,000 IU or less of vitamin A daily), and an inability to avoid aspirin- or ibuprofen-containing products 2 weeks before injection sessions (acetaminophen derivatives were allowed). Patients were told not to use any medicated products around the eyes (e.g., corticosteroids), "antiwrinkle" products, or any over-the-counter aspirin- or ibuprofen-containing products.

Preprocedure examination included evaluation of location and size measurement of the infraorbital fat pads, inquiry and examination for any concomitant ocular or periocular pathology, systemic disease, and digital photography.

Injectable phosphatidylcholine at a concentration of 50 mg/mL was compounded under sterile conditions using United States Pharmacopeia-grade phosphatidylcholine (Table 1). The phosphatidylcholine used in our study was acquired from the manufacturer of an oral phosphatidylcholine nutritional supplement (American Lecithin Company, Oxford, CT). This substance is derived from soybean lecithins, half of which is composed of phospholipids. Phosphatidylethanolamine, phosphatidylinositol, and phosphatidic acid fractions naturally present in lecithin were removed, yielding 96% phosphatidylcholine. Moisture, neutral oils, and lysophosphatidylcholine, a natural degradation product, compose the balance. The other ingredients, similar to those found in the pharmaceutically prepared formulations, include sodium deoxycholate (a bile salt used to transform phosphatidylcholine into micelles small enough to pass through the sterile filtration manufacturing process), benzyl alcohol (a preservative and solubility factor), and sterile water (Zigmont RE, personal communication, March 2003).

After 5 minutes of applying an ice compress to the infraorbital skin, the injection procedure consisted of sitting the patient upright, pulling the skin of the lower lid downward with the forefinger, and gently pressing

on the superior globe for enhanced fat pad visualization. A 0.5-inch, 30-gauge needle was used to inject 0.4 mL of phosphatidylcholine approximately 0.5 cm deep into the unanesthetized infraorbital fat pads. Based on the individual's distribution of fat along the infraorbital bulge, the medication was divided among the central, medial, and lateral fat pads. Both lower eyelids were injected at each session. An ice compress was then reapplied to the infraorbital skin for 10 minutes. Patients were instructed to remain upright for at least 4 hours after the procedure, not to engage in any vigorous physical activity for the rest of the day, and to sleep with their heads elevated to the height of at least two pillows the night of the treatment.

Patients were evaluated and injected at the beginning of the study and at 14-day intervals. The injecting physician remained the same throughout the study. No more than five injection sessions were performed. Treatment was discontinued at any time on request by the patient or if the injecting physician did not believe the patient would benefit from additional treatment. Both physician and patient were asked to score the degree of infraorbital fat herniation before any treatment (visit 1) as the baseline for comparison at follow-up. Patients were asked to report the presence and duration of any side effects developing after the previous injection (swelling, erythema, etc.). In addition, digital photographs were taken before injections. To reduce intraevaluator and interevaluator bias, both patient and physician were unaware of his or her previous evaluations and of the other's evaluations. Patient grading was given to the nurse before treatment, and physician grading was recorded separately.

Patient self-assessment of infraorbital fat herniation was graded as mild (0–3), moderate (4–7), or severe (8–10). Physician grading of fat herniation was recorded as mild (0–3, fat herniation seen none to less than 1 mm above surrounding skin), moderate (4–7, fat herniation 1 to 2 mm above surrounding skin surface), and severe (8–10, fat herniation more than 2 mm elevation above surrounding skin surface).

A follow-up questionnaire was administered by telephone at least 6 months after the last treatment. Patient satisfaction was graded along a scale as 1 (unsatisfied) 5 (ambivalent), to 10 (very satisfied). The persistence of benefit (if any) was graded along a scale as 1 (my eyes look the same now as they looked before treatment), 5 (the results faded somewhat), to 10 (the benefit achieved have remained the same). Patients were also asked whether they would recommend the procedure to a friend and whether they would have paid for it. Additional comments about side effects and suggestions were solicited at that time as well. Three patients were digitally photographed 9 months after their last injections.

Table 1. Formula for Injectable Phosphatidylcholine (5%)

Phosphatidylcholine, USP (96%)	5 g
Deoxycholic acid, sodium salt (99%)	4.75 g
Benzyl alcohol (99.9%)	0.9 mL
Sterile Water for injection, USP	100 mL

**Results**

Thirteen patients were enrolled in the study, which was conducted in a private practice setting. Patient age ranged from 42 to 71 years (mean, 52.3 years) consisting of 10 women and 3 men (Table 2). All patients were skin types I–III, with the exception of one patient with Fitzpatrick skin type V, who was later lost to follow-up. From January 2002 to November 2002, a total of 49 injection sessions (consisting of treatment to both eyes) were performed, ranging from one to five sessions per patient (Table 2).

At 14-day intervals, seven patients received five injections. One patient received four injections (after the physician thought that she would no longer benefit from an additional injection). Two patients received three injections (one patient moved, and the other decided to discontinue because of a negligible response). One patient received two injections, and two patients received one injection. The three patients who had one or two injections were excluded from the study because of insufficient follow-up data: one patient was lost to contact, one discontinued treatment because of loss of interest, and one moved to a distant location. Analysis was conducted on the remaining 10 patients, aged 42–71 years (mean, 53.4 years), consisting of 7 women and 3 men.

**Infraorbital Fat Herniation**

The physician noted improvement in fat herniation in eight patients (80%) with a mean of 3.4 points (Figure 1). Seven patients (70%) reported improvements in fat herniation, with a mean of 4.3 points (Figure 2). Six patients (60%, patients 1–6) assessed their improvement as equal or greater than 5 points. However, the physician judged only four patients (40%, patients 1,

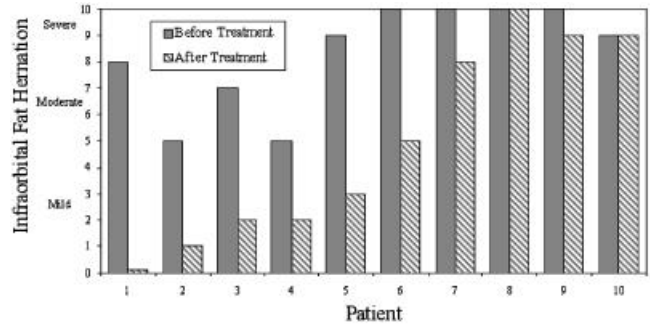


Figure 1. Physician evaluation of infraorbital fat herniation before and after treatment.

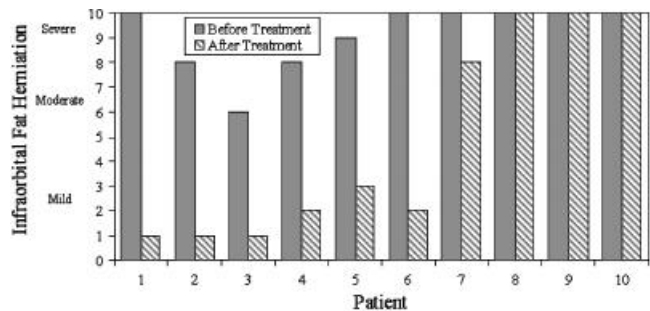


Figure 2. Patient self-assessment of infraorbital fat herniation before and after treatment.

3, 5, and 6) improving to this degree. In accord with the physician’s evaluation, three patients (30%) graded 1 point or no change in fat herniation.

There was good concordance between physician and patient scores throughout the study (data not shown) despite at least a 2-point difference in patients 1, 2, and 4 before treatment. At the conclusion of the study, there was at most a 1-point difference between the physician and patient fat herniation scores in all patients except patient 6, who had a 3-point difference.

In general, for those patients who responded after the first treatment, subsequent injection produced additional improvements in fat herniation (data not shown). There was no relationship between the degree of improvement in fat herniation and age, gender, or side effects. Figure 3A–C shows three patients at follow-up after their injections.

**Adverse Effects**

Burning at the injection site, which was felt by all patients immediately after the phosphatidylcholine injection, resolved within 10 minutes. Table 3 summarizes the duration of edema and erythema experienced by the study participants after each treatment. In all patients, swelling was observed within the

Table 2. Patient Demographics and Treatments

Patient	Gender	Age	Treatments
1	F	56	4
2	F	56	5
3	M	42	5
4	F	62	5
5	F	71	5
6	M	42	5
7	F	50	3
8	F	50	5
9	F	54	5
10	M	52	3
11	F	54	1
12	F	42	2
13	F	49	1

Dermatol Surg 30:3:March 2004

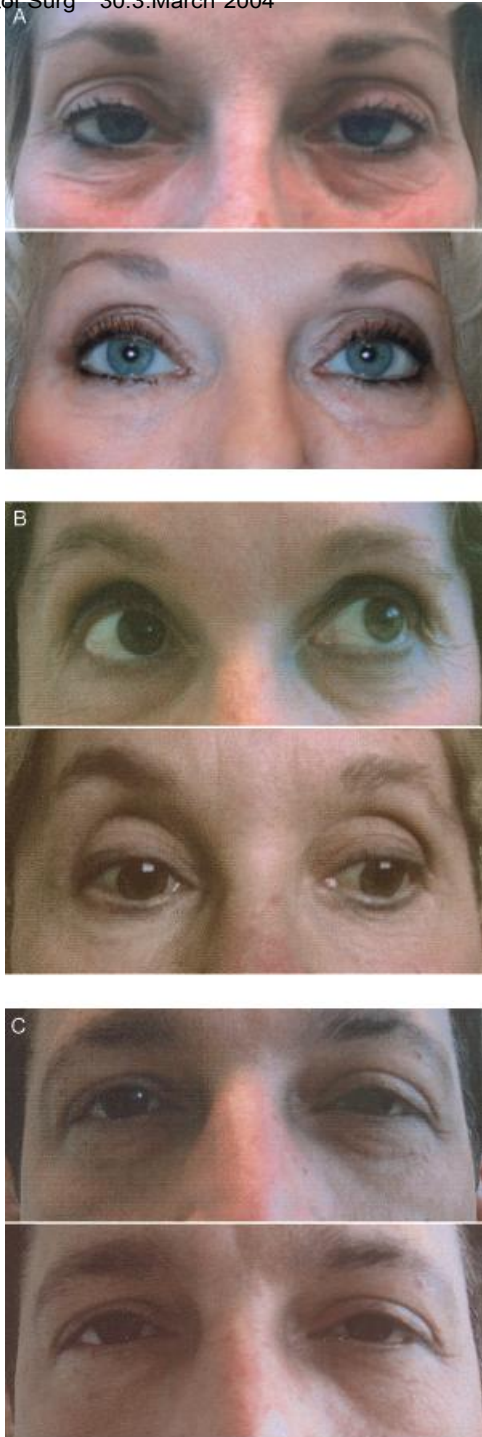

Figure 3. (A) Patient 1 before and at follow-up after four treatments. (B) Patient 2 before treatment and at follow-up 9 months after treatment. (C) Patient 3 before treatment and at follow-up after five treatments.

infraorbital region immediately after injection. This resolved in three patients consistently during their visits. Only one participant (patient 6) experienced neither erythema nor prolonged edema (lasting beyond the time for the injected solution to disperse). Seven

Table 3. Adverse Effects

Patient	Treatments With Edema Resolving Within 3 Days/Total Treatments Received	Treatments With Edema Persisting Beyond 3 Days/Total Treatments Received	Treatments With Transient Erythema <sup>a</sup> /Total Treatments Received
	1	0/4	1/4 <sup>n</sup>
2	5/5	0/5	3/5
3	3/5	0/5	1/5
4	3/5	0/5	1/5
5	0/5	2/5	3/5
6	0/5	0/5	0/5
7	3/3	0/3	3/3
8	5/5	0/5	1/5
9	5/5	0/5	1/5
10	3/3	0/3	2/3

<sup>n</sup> Significant swelling, see text for details.

<sup>w</sup> Lasting several hours to 2 days.

patients (70%) reported minor swelling at the injection site, resolving within 3 days of the injections. Two patients (20%) experienced edema that lasted beyond 3 days and resolved within 1 week. Of these, one patient (patient 1) had a significant reaction after her first injection. The other patient (patient 5) had moderate swelling at the injection site twice out of her five treatments that did not require intervention.

Patient 1 developed significant, painless swelling with mild erythema in the infraorbital soft tissue after her first treatment that persisted for 7 days (Figure 4). Visual disturbances, conjunctivitis, purulent discharge, extension into the orbit, or tenderness were not reported or evident on physical examination. The edema diminished within 5 days after treatment with a 5-day taper of prednisone. This patient did not experience significant swelling after subsequent injections.

Erythema at the injection site was observed in nine patients (90%) immediately after the injection at least once during their treatment (Table 3). All patients had clearing of the erythema several hours to 2 days after injection.

Blurred vision or other visual field defects, conjunctivitis, persistent erythema, change in lid shape or skin texture, hematoma, infection, headache, nausea, urticaria, anaphylaxis, and/or constitutional symptoms were not observed by the physician nor were they reported by the study participants at any time during the study or at follow-up.

#### Follow-Up Questionnaire

All 10 patients completing the study were contacted by telephone between 6 and 10 months (mean, 9 months)

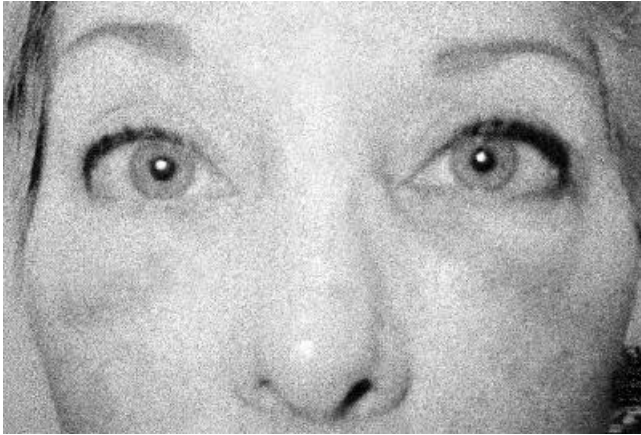

Figure 4. Patient 1 with infraorbital swelling 2 days after her first phosphatidylcholine injections.

Table 4. Questionnaire Feedback

	Yes	No
Recommend injections to a friend?	80%	20%
Pay for it if you had to?	70%	30%

after their last treatment. A majority of patients (70%) were satisfied or very satisfied with the results (grading satisfaction 7 or higher). Two were ambivalent, and one was unsatisfied. Patients demonstrating greatest benefit from the treatment reported the most satisfaction. Patients 8, 9, and 10—none of whom had noticeable improvement—felt either ambivalent or unsatisfied with their results.

Five patients (50%; patients 1, 2, 5, 6, and 7) reported persistence or near persistence of results over time at follow-up between 8 and 10 months. Patients 3 and 9, the latter who experienced minimal benefit from the treatment, reported some fading over time. Three patients (4, 8, and 10) stated that their eyes appeared the same as they were before entering the study. Despite initial improvement, patient 4 had the benefit diminish after 6 months. Eighty percent of patients would recommend this treatment to a friend, and 70% would have paid for the procedure (Table 4).

## Discussion

We report an open-label study evaluating the efficacy and safety of injectable phosphatidylcholine for the treatment of infraorbital fat pads. Most, but not all, of our patients obtained cosmetic improvement in infraorbital fat herniation, which impressed them more than the evaluating physician. The absence of a standardized grading scale precludes comparing one

patient's score to that of another; nevertheless, a general trend in improvement of infraorbital herniation in most patients supports the observations of the physician.

There are several differences in outcome and methods between our study and the previous report by Rittes<sup>5</sup> regarding number of treatment sessions and patient response. Most patients (23 of 30) in the prior study received only one or two injections after it was thought that additional injections would not benefit the patient.<sup>5</sup> In contrast, benefit was observed in most of our patients after each treatment. Several patients may have had continued benefit with additional injections, but treatment was discontinued after five injections given the lack of established treatment protocol and unknown potential side effects. We found that with the exception of patient 4, patients who benefited the most after treatments had the longest persistence of results over time (up to 10 months at follow-up).

Three patients (8, 9, and 10) had no clinical improvement from the phosphatidylcholine treatment. However, we were unable to stratify patients to response based on age, gender, or immediate reaction to injection (burning, edema, erythema) because of limited sample size. Despite visualization of the fat pads on examination, it may be that patients who failed to respond had excessive hypertrophied muscle, rather than exclusively fat herniation. Based on her experience with over 600 patients, Rittes (personal communications, March 2003) believes that phosphatidylcholine has no apparent clinical effect on muscle tissue.

Adverse effects reported by this and the previous study were transient burning, erythema at the injection site, and mild infraorbital swelling resolving in most patients within 3 days.<sup>5</sup> However, the previous study did not report swelling beyond 3 days in any of the 30 subjects.<sup>5</sup> In our study, one patient experienced considerable swelling lasting 7 days that resolved after treatment with systemic corticosteroids. It is unknown whether the edema would have subsided without treatment but possible given the experience of the other patients. None of our patients withdrew from the study because of adverse effects.

Injectable phosphatidylcholine is available as Lipostabil (Aventis Pharmaceuticals) and Essentiale (Rhone-Poulenc Rorer). It is used worldwide for several medical conditions, including hyperlipidemia, peripheral vascular disease, cardiac ischemia, and liver disease.<sup>7-13</sup> Since the published study by Rittes, treatment of localized fat collections using a phosphatidylcholine formula (especially on the thighs, abdomen, chin, and arms) has been escalating. Although limited in objective evaluation, a recent case series of over 200

patients treated with injectable phosphatidylcholine noted an unspecific reduction in subcutaneous fat in a "vast majority of patients."<sup>6</sup> This report noted transient local reactions similar to those reported herein and did not describe any laboratory abnormalities or systemic complications. At the time of this study, there is considerable controversy over the use of Lipostabil and Essentiale, both non-FDA-approved drugs, in the United States. The media has publicized their use (advertised by some dermatologists as Lipo-Dissolve and Lipolight) as an alternative to liposuction. However, despite increasing reports of its effectiveness in these areas, there are no double-blinded, placebo-controlled clinical trials demonstrating the efficacy and potential long-term side effects of injectable phosphatidylcholine. To our knowledge, there are no Food and Drug Administration trials investigating injectable phosphatidylcholine.

In vitro and in vivo studies on intravenous or oral polyenylphosphatidylcholine (another name for phosphatidylcholine, as linoleic acid [a fatty acid] is bound to a majority of the molecules) have demonstrated antioxidant and antifibrotic effects mediated by anticollagenase activity.<sup>14-19</sup> Preliminary experiments on the phosphatidylcholine formulation used in our study have demonstrated lysis of keratinocyte cell membranes in vitro (unpublished data). Further investigation into the mechanism of action of phosphatidylcholine in fat tissue and its clinical effect on other anatomic sites are presently underway. Larger studies will determine optimal dosage, frequency, injection technique, and potentially additional adverse effects.

Overall, a majority of our patients were satisfied with the results of the phosphatidylcholine injections to the extent that they would have paid for the procedure and would recommend it to others. Relative to blepharoplasty, phosphatidylcholine injections may carry a decreased risk of scarring, asymmetry, trauma, ectropion, and prolonged recovery time. Despite its limitations, this study may assist physicians in evaluating the efficacy and utility of this novel substance. Although our findings suggest that phosphatidylcholine has promise for cosmetic applications, we urge physicians to use caution until it is evaluated in a larger population of patients.

**Acknowledgments** The authors would like to thank Randy Zigmont and Gene Ragazzo for their technical assistance and

advice in preparation of this manuscript. We are especially grateful to Michael Kolodney, MD, PhD, for his editorial assistance.

## References

1. American Society of Plastic Surgeons and Plastic Surgery Educational Foundation Website, Vol. 2003. Plastic Surgery Information Service, 2001.
2. Sachs ME, Bosniak SL. Correction of true periorbital fat herniation in cosmetic lower lid blepharoplasty. *Aesthetic Plast Surg* 1986;10:111-4.
3. Wenzel J, Gerdson R, Christ S, Bieber T, Uerlich M. Infraorbital eyelid edema as the presenting sign of bronchogenic carcinoma. *Int J Dermatol* 2002;41:386-7.
4. Thomasse Y, van Unen H, van Collenburg JJ, van Elburg RM. Child with swelling of eyelids and face: not always due to allergy. *Ned Tijdschr Geneesk* 1999;143:1761-3.
5. Rittes PG. The use of phosphatidylcholine for correction of lower lid bulging due to prominent fat pads. *Dermatol Surg* 2001;27:391-2.
6. Hexsel D, Serra M, Mazzuco R, Dal'Forno T, Zechmeister D. Phosphatidylcholine in the treatment of localized fat. *J Drugs Dermatol* 2003;2:511-8.
7. Lieber CS. Alcoholic liver injury: pathogenesis and therapy in 2001. *Pathol Biol* 2001;49:738-52.
8. Bobkova VI, Lokshina LI, Korsunskii VN, Tananova GV. Metabolic effect of lipostabil-forte. *Kardiologiya* 1989;29:57-60.
9. Khashimov KhA, Okur F, Orekhov AN, Kurdanov KhA, Tertov V. Effect of lipostabil on cholesterol levels in atherosclerotic plaques of the human aorta and the aggregative capacity of thrombocytes (in vitro study). *Biull Vsesoiuznogo Kardiolog Nauchn Tsentra AMN SSSR* 1988;11:95-8.
10. Dobiasova M, Stribrna J, Matousovic K. Effect of polyenoic phospholipid therapy on lecithin cholesterol acyltransferase activity in the human serum. *Physiol Bohemoslov* 1988;37:165-72.
11. Kirsten R, Heintz B, Nelson K, et al. Polyenylphosphatidylcholine improves the lipoprotein profile in diabetic patients. *Int J Clin Pharmacol Ther* 1994;32:53-6.
12. Ma X, Zhao J, Lieber CS. Polyenylphosphatidylcholine attenuates non-alcoholic hepatic fibrosis and accelerates its regression. *J Hepatol* 1996;24:604-13.
13. Pogozheva AV, Bobkova SN, Samsonov MA, Vasilev AV. Comparative evaluation of hypolipidemic effects of omega-3 polyunsaturated acids and lipostabil. *Vopr Pitan* 1996;431-3.
14. Lieber CS, DeCarli LM, Mak KM, Kim CI, Leo MA. Attenuation of alcohol-induced hepatic fibrosis by polyunsaturated lecithin. *Hepatology* 1990;12:1390-8.
15. Lieber CS, DeCarli LM. Animal models of chronic ethanol toxicity. *Methods Enzymol* 1994;233:585-94.
16. Navder KP, Baraona E, Lieber CS. Polyenylphosphatidylcholine attenuates alcohol-induced fatty liver and hyperlipemia in rats. *J Nutr* 1997;127:1800-6.
17. Lieber CS, Robins SJ, Li J, et al. Phosphatidylcholine protects against fibrosis and cirrhosis in the baboon. *Gastroenterology* 1994;106:152-9.
18. Lieber CS, Leo MA, Aleynik SI, Aleynik MK, DeCarli LM. Polyenylphosphatidylcholine decreases alcohol-induced oxidative stress in the baboon. *Alcohol Clin Exp Res* 1997;21:375-9.
19. Cao Q, Mak KM, Lieber CS. Dilinoleoylphosphatidylcholine prevents transforming growth factor-beta1-mediated collagen accumulation in cultured rat hepatic stellate cells. *J Lab Clin Med* 2002;139:202-10.