
Lipomas treated with subcutaneous deoxycholate injections

Adam M. Rotunda, MD,^a Glynis Ablon, MD,^b and Michael S. Kolodney, MD, PhD^c
Los Angeles and Torrance, California

Background: Lipomas are benign neoplasms of mature fat cells. Current treatments are invasive and carry the risk of scarring. Injections of phosphatidylcholine solubilized with deoxycholate, a bile salt, have been used to reduce unwanted accumulations of fat. Recent in vitro and ex vivo investigations indicate that deoxycholate alone causes adipocyte lysis.

Objective: We sought to report our experience treating lipomas using subcutaneous deoxycholate injections.

Methods: A total of 6 patients presenting with 12 lipomas were treated with intralesional injections of sodium deoxycholate (1.0%, 2.5%, and 5.0%) at intervals of 2 to 20 weeks. Tumor size, cutaneous reactions, and patients' subjective responses were recorded before and after treatment.

Results: All lipomas decreased in size (mean area reduction, 75%; range, 37%-100%) as determined by clinical measurement (with ultrasound confirmation in one lipoma) after an average of 2.2 treatments. Several lipomas fragmented or became softer in addition to decreasing in volume. Adverse effects, including transient burning, erythema, and local swelling, were associated with higher deoxycholate concentrations but resolved without intervention. There was no clear association between deoxycholate concentration and efficacy.

Conclusions: Our clinical experience supports our laboratory investigations demonstrating that deoxycholate, rather than phosphatidylcholine, is the active ingredient in subcutaneously injected formulas used to treat adipose tissue. This small series suggests that low concentration deoxycholate may be a relatively safe and effective treatment for small collections of fat. However, controlled clinical trials will be necessary to substantiate these observations. (J Am Acad Dermatol 2005;53:973-8.)

Lipomas are relatively common, subcutaneous neoplasms of mature fat cells that may extend intramuscularly or along deep fascial planes.^{1,2} Patients often request removal of their

lipomas as a result of concerns about growth, cosmesis, or because of symptoms arising from compression of local structures. Treatment traditionally includes surgical excision or liposuction depending on the size, anatomic location, and clinical characteristics of these relatively common, slowly growing mesenchymal neoplasms.^{1,3,4} Although effective, these modalities are associated with the risk of scarring, seroma, and hematoma formation.^{3,5} Treatments that are minimally invasive and not associated with these risks would be ideal for patients with multiple lipomas or those reluctant to undergo operation.

Several open-label clinical trials have reported localized loss of adipose tissue using subcutaneous injections of a mixture containing phosphatidylcholine and the bile salt, sodium deoxycholate, which is used to solubilize the lecithin-derived phospholipid.⁶⁻⁹ As a result, these treatments are becoming increasingly popular and have been labeled colloquially as "mesotherapy."^{10,11}

Our recent laboratory investigations demonstrate that isolated sodium deoxycholate is as potent at

From the Division of Dermatology, University of California Los Angeles, David Geffen School of Medicine^a; Department of Dermatology, West Los Angeles Veteran Administration Medical Center^b; and Division of Dermatology, Department of Medicine, Harbor-UCLA Medical Center and Los Angeles Biomedical Research Institute, Torrance.^c

Funding sources: None.

Disclosure: Drs Rotunda and Kolodney are co-developers of a patent-pending process owned by the Los Angeles Biomedical Institute and University of California Los Angeles that describes the use of detergents for the reduction of fat. The authors had no commercial interests or financial support for their work.

Accepted for publication July 30, 2005.

Reprint requests: Adam M. Rotunda, MD, Bennett Surgery Center, St. John's Medical Plaza, Suite 590, Santa Monica, CA 90404.

E-mail: arotunda@hotmail.com.

Published online October 17, 2005.

0190-9622/\$30.00

© 2005 by the American Academy of Dermatology, Inc.

doi:10.1016/j.jaad.2005.07.068

Table I. Pretreatment and posttreatment size, change in area, total treatments, interval between treatments, and interval between last treatment and final measurement for lipomas injected with the indicated concentrations of sodium deoxycholate

Lipoma	Site	Pretreatment size, cm	Posttreatment size, cm	Change in area, %	Total number of treatments (% deoxycholate injected)	Interval between treatments	Interval between last treatment and final measurement
1	Upper abdomen	1	0*	-100	1 (2.5%)	N/A	6 mo
2	Upper abdomen	2	1.0, 0.3, 0.5 (3 pieces) [†]	N/A	3 (5%, 5%, 2.5%)	2 wk-5 mo	4 mo
3	Lower abdomen	2 × 2.5	1 × 1.5	-70	3 (5%, 5%, 2.5%)	2 wk-5 mo	4 mo
4	Upper back	4 × 3.5	2	-71	4 (1%)	1-4 mo	4 mo
5	Clavicle	2 × 1.8	1.3	-82	4 (1%)	1-4 mo	4 mo
6	Forearm	2.8	0.5	-97	1 (5%)	N/A	3 mo
7	Shoulder	3 × 2 (2.6 × 0.6 by ultrasound)	0.8 (0.5 × 0.3 by ultrasound)	-90 [§]	2 (1%)	5 mo	4 mo
8	Forearm	1 (1.2 × 0.9 by ultrasound)	0*	-100	2 (1%)	4 mo	4 mo
9	Upper thigh	2 × 1	1.2 × 0.8	-52	2 (2.5%)	3 mo	4 mo
10	Chest	2	1.3 ^{††}	-58	2 (5%, 1%)	5 mo	5 mo
11	Forearm	2	1.4 × 1 [‡]	-65	1 (5%)	N/A	2 wk
12	Forearm	1	0.8	-37	1 (5%)	N/A	5 mo

N/A, Not applicable.

*Imperceptible size precluded clinical measurement.

†Fragmented.

‡Excised after final injection.

§Based on ultrasound measurements.

||Single number refers to diameter.

causing adipocyte lysis as a mixture also containing phosphatidylcholine.¹² These findings suggest that deoxycholate is the primary active ingredient in this formulation and may lead to fat reduction clinically. Herein, we report a case series of patients treated with subcutaneous injections using deoxycholate alone as a treatment for their lipomas.

METHODS

After obtaining informed consent for treatment, 6 patients with 12 clinically diagnosed lipomas (two confirmed by ultrasound) were injected with a solution containing sodium deoxycholate (at concentrations of 50, 25, or 10 mg/mL), benzyl alcohol (9 mg/mL), and sterile water (Hopewell Compounding Pharmacy, Hopewell, NJ). Patients did not report any significant medical history, nor had they had previous intervention to the lipomas undergoing treatment. The same clinician who performed the injections also evaluated lipoma size (measured by ruler), consistency, location, and shape before treatment and at follow-up. A 30-gauge, .5-in needle attached to a 3-mL syringe was used to directly inject the solution transcutaneously into the lipoma. No ice, or topical or local anesthetic, was used. We did not

massage, perform subcision on, or physically manipulate the lipoma before or after injection. Patients were treated with a volume of solution in milliliters equal to half of the largest dimension of the lipoma in centimeters. When the lipoma measured more than 1 cm, injections were placed at two equally spaced sites. Pressure was applied directly to the site of injection for several seconds to prevent local bleeding and an adhesive dressing was applied. No specific wound care was advised. The patient's clinical responses, including pain and erythema, were recorded immediately after injection. Additional reactions occurring in the interval between treatments were recorded by the patient and reported at the subsequent visit. Intervals between injections were chosen at least 2 weeks in length. Treatment was continued until the patient was satisfied with the lipoma's response to the injection. Deoxycholate concentration was titrated down to comfort on subsequent visits according to the reported side effects. Several lipomas were photographed before and immediately after injection, and at follow-up. One lipoma was evaluated by ultrasound both before commencing the injections and after completing the treatment.

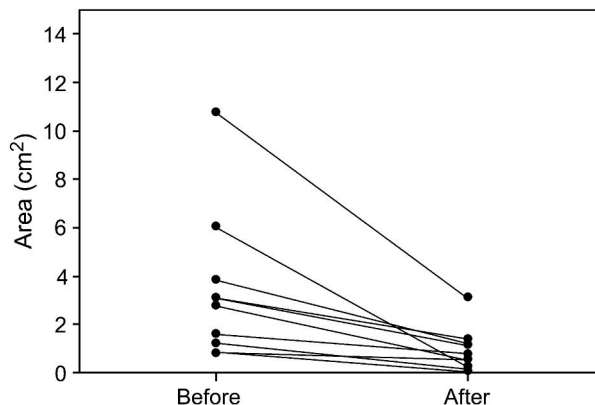


Fig 1. Lipoma area before and after subcutaneous deoxycholate injections.

RESULTS

A total of 12 subcutaneous lipomas in 6 patients (3 men and 3 women, age 33-43 years, Fitzpatrick skin type II-IV) were injected with varying concentrations of sodium deoxycholate. Our observations are summarized in Table I and Fig 1. All lipomas were reduced in size (average area reduction 75%) after a mean of 2.2 treatments (4 lipomas were treated once; 4 lipomas were treated twice, 2 lipomas were treated 3 times; and 2 lipomas were treated 4 times). All lesions treated with 1% deoxycholate alone (lipomas 4, 5, 7, and 8) had a decrease in area within the range (37%-100%) of those treated with 2.5% or 5.0% deoxycholate. The time interval between treatments ranged from 2 weeks to 5 months due to a number of factors unrelated to clinical response or treatment effects.

The ultrasound dimensions of lipomas 7 and 8 closely correlated with their measurements on physical examination (Table I and Fig 2). Lipomas that were firm to palpation on initial physical examination (lipomas 1-3 and 9) became softer after the first injection. Two lesions (lipoma 2, 2 cm, upper abdomen; and lipoma 10, 2 cm, chest) fragmented at the injected sites. Specifically, lipoma 2 became softer and divided into what was thought to be 3 distinct lesions 8 weeks after the last injection (Fig 3). Lipoma 10 fragmented at the two injection sites during the 5-month follow-up interval, but otherwise remained intact. In two cases (lipomas 4 and 5), skin that was considerably distended by the underlying lipoma on physical examination before treatment became significantly flatter at subsequent visits. Although these lipomas were not dramatically reduced in diameter even after 4 treatments, this outcome was judged to be cosmetically acceptable to the patients.

Patients were treated with a reduced deoxycholate concentration over time given the side effects

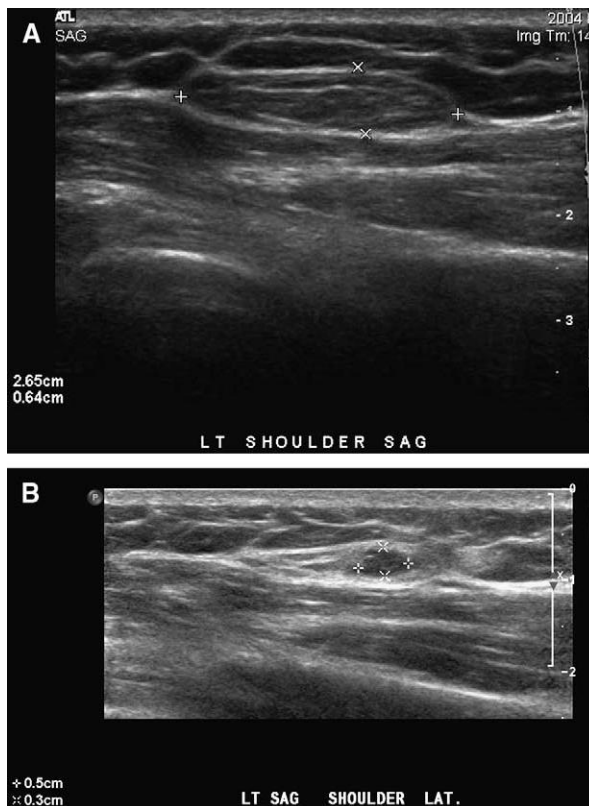


Fig 2. **A**, Ultrasound of lipoma 7 located on the shoulder measuring 2.65 × 0.64 cm before treatment. **B**, Same lipoma measuring 0.5 × 0.3 cm 4 months after second and last injection.

associated with higher concentrations (Table II). Notably, most patients treated with 5.0% or 2.5% deoxycholate experienced moderate to severe burning within minutes of injection and mild, sustained localized swelling (≤ 6 weeks). Cutaneous paresthesias (numbness with loss of soft touch and pinprick sensation) lasting up to 6 weeks was noted overlying lipomas 6 and 11 (from the forearm of two separate patients), both of which were injected with the 5.0% deoxycholate. The dysesthesia spontaneously resolved after the swelling subsided, although one patient eventually decided to have this lipoma excised (lipoma 11). Intraoperatively, a nerve (confirmed by visualization and manipulation) was adjacent to the lipoma. Ecchymoses occurred in two patients, both of whom bled at the injection site. This response did not correlate with deoxycholate concentration.

In contrast to higher concentrations, 1% deoxycholate caused significantly less side effects. Several patients reported no discomfort at any point in time after injection. Adverse effects at this concentration included mild burning persisting no longer than 24 hours; erythema lasting for 24 hours to 5 days; and

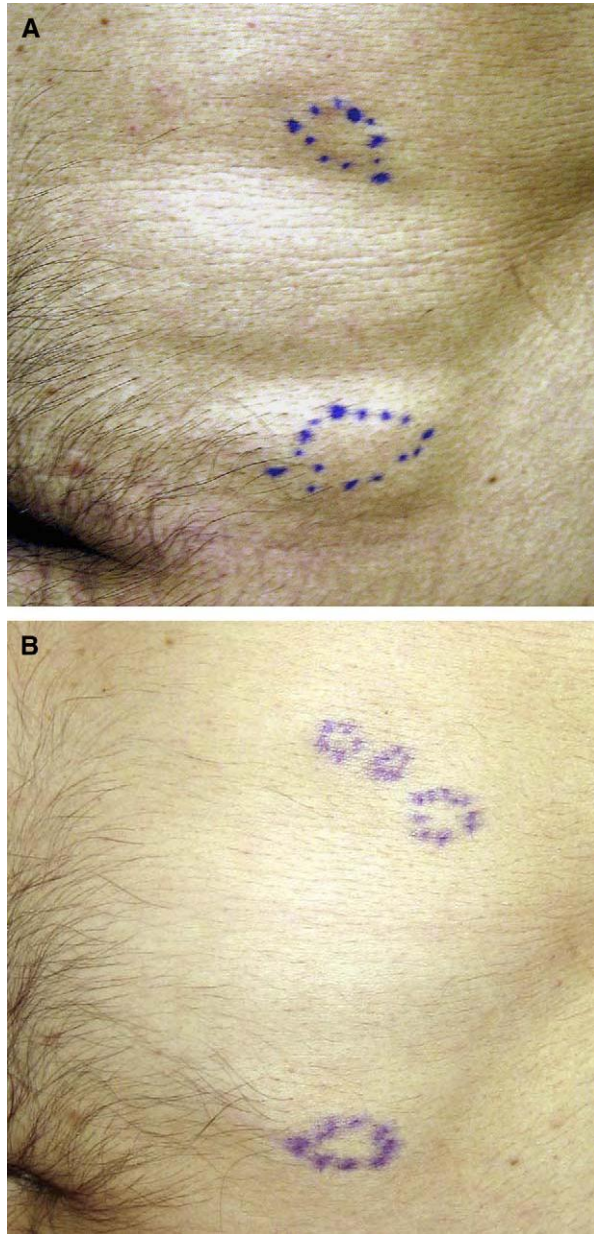


Fig 3. Lipomas 2 and 3 before (A) and after (B) treatment. Lipoma 2 fragmented into 3 distinct lesions 4 months after third and last injection.

several days of very mild swelling and tenderness. Cutaneous anesthesia was not reported in patients receiving 1% deoxycholate.

Gross and histologic findings of an excised lipoma 2 days after injection are reported elsewhere.¹¹ There was no ulceration, scarring, dyspigmentation, or other prolonged local side effects noted at follow-up (occurring \leq 1 year after injection of 5% deoxycholate). No patient reported constitutional symptoms at any time during treatment.

Table II. Clinical response and duration of reaction based on clinician and patient observations after injections

Reaction	Duration	Comments
Burning	30 min-24 h	None-very mild (1% deoxycholate) or severe (2.5% and 5.0% deoxycholate)
Erythema	24 h-5 days	Mild-moderate in all patients; longer duration more common with 2.5% and 5.0% deoxycholate
Tenderness	Several days-weeks	Very mild-moderate in all patients; longer duration and higher intensity related to increasing concentrations
Echymoses	10 and 14 days	Occurred in two patients (using 1% and 5% deoxycholate) who experienced bleeding at the injection site
Cutaneous anesthesia (to pinprick, soft touch)	4 and 6 wk	Occurred in two patients with forearm lipomas injected with 5% deoxycholate; resolved without intervention in both cases

DISCUSSION

The cosmetic treatment of adipose tissue with injections of herbal and/or medicinal compounds has received recent attention in the lay press¹³⁻¹⁵ and medical literature^{10,11,16} under the rubric "mesotherapy." A common ingredient in these preparations is phosphatidylcholine, which is invariably combined with deoxycholate to facilitate suspension of the phospholipid in an aqueous solution. Deoxycholate is a secondary bile salt that has been incorporated as an emulsifier in intravenous medication.¹⁷⁻²⁰ As with other physiologic bile salts, deoxycholate possesses detergent properties with polar lipids.^{21,22} This detergent action was recently shown to produce human keratinocyte cell lysis in

vitro and disruption of porcine adipose architecture *ex vivo*.¹² Injection of deoxycholate into human lipomas causes focal necrosis, acute inflammation, and hemorrhage histologically.¹¹ The specificity of the effects of bile salts on fat relative to other tissue is presently under investigation.

We have observed the clinical use of the detergent effects of deoxycholate after subcutaneous injection into lipomas. All lipomas decreased in size clinically, which was confirmed by ultrasound in one case. These findings support the conclusion that deoxycholate is the major active component of the formulation also containing phosphatidylcholine. Moreover, phosphatidylcholine is not necessary to produce these effects.

High concentrations of deoxycholate are associated with more severe and prolonged side effects including cutaneous anesthesia, which may be related to the localized inflammatory reaction and/or a direct caustic effect of deoxycholate on nerves. Two patients reported paresthesias of the skin overlying forearm lipomas after injection with 5% deoxycholate. This effect was likely related to the higher deoxycholate concentration and their proximity to local nerves, as evident in one surgically excised lipoma. Low concentration (1%) was uniformly tolerated by all patients and not associated with any significant adverse events.

Our previous studies suggest that deoxycholate destroys adipocytes through lysis of cell membranes.¹² However, the ultimate fate of the triglyceride contained within the adipocytes remains unknown. A report by Hexsel et al⁹ performed baseline, intratreatment, and posttreatment (2 weeks) laboratory analysis in 13 of 213 patients receiving a combination of phosphatidylcholine and deoxycholate for localized fat loss. No significant alterations in hepatic or lipid profiles were recorded in all 13 patients who were tested. Our patients' clinical response together with the histology of injected fat, which includes acute inflammation,¹¹ lipid-laden macrophages, and subsequent fibrosis (unpublished data), suggests that the insoluble triglyceride is gradually removed by inflammatory cells. However, some of the triglyceride may be converted to fatty acids, monoglycerides and diglycerides, and glycerol by cellular or serum lipases.

Our previous experimental data indicate that 5% deoxycholate does not produce any additional loss of cell viability or cell lysis compared with 0.5% deoxycholate.¹² Our clinical observations similarly reflect that there does not appear to be a relationship between clinical response (change in lipoma size) and deoxycholate at the concentrations used in these patients. Patients treated with the lowest (1%) dose of deoxycholate had as good as or better response

compared with those patients treated with higher concentrations. Once a minimum effective deoxycholate concentration is attained, increasing detergent concentration may no longer confer additional dissolution of the lipoma, but instead contribute to adverse effects (burning, prolonged induration, paresthesias). Additional studies using varied concentrations of detergent held at fixed volumes would be required before a definitive conclusion regarding the ideal deoxycholate concentration is reached.

Patients may prefer minimally invasive procedures, even if outcomes are less dramatic or rapid than more invasive techniques. Subcutaneous injection of low-concentration deoxycholate or similar detergents may become a nonsurgical treatment for lipomas. Clinical studies investigating dose response and the safety profile of deoxycholate are necessary for intralesional bile salt injections to become a viable therapeutic option for the removal of localized fat.

REFERENCES

1. Ragsdale BD. Tumors with fatty, muscular, osseous, and cartilaginous differentiation. In: Elder DE, Elenitsas R, Johnson BL Jr, Murphy GF, editors. *Lever's histopathology of the skin*. Philadelphia: Lippincott Williams and Wilkins; 2004. pp. 1061-107.
2. Dolsky RL, Asken S, Nguyen RL. Surgical removal of lipoma by lipo-suction surgery. *Am J Cosmetic Surg* 1986;3:27.
3. Chandawarkar RY, Rodriguez P, Roussalis J, Tantri MD. Minimal-scar segmental extraction of lipomas: study of 122 consecutive procedures. *Dermatol Surg* 2005;31:59-63.
4. Field LM. Lipo-suction surgery: a review. *J Dermatol Surg Oncol* 1984;10:530-8.
5. Gingrass MK. Lipoplasty complications and their prevention. *Clin Plast Surg* 1999;26:341-54.
6. Rittes PG. The use of phosphatidylcholine for correction of localized fat deposits. *Aesthetic Plast Surg* 2003;27:315-8.
7. Rittes PG. The use of phosphatidylcholine for correction of lower lid bulging due to prominent fat pads. *Dermatol Surg* 2001;27:391-2.
8. Ablon G, Rotunda AM. Treatment of lower eyelid fat pads using phosphatidylcholine: clinical trial and review. *Dermatol Surg* 2004;30:422-7.
9. Hexsel D, Serra M, Mazzuco R, Dal'Forno T, Zechmeister D. Phosphatidylcholine in the treatment of localized fat. *J Drugs Dermatol* 2003;2:511-8.
10. Rohrich R. Mesotherapy: what is it? Does it work? *Plast Reconstr Surg* 2005;115:1425.
11. Rotunda AM, Kolodney MS. Mesotherapy and phosphatidylcholine injections: historical clarification and review. *Dermatol Surg*. In Press.
12. Rotunda AM, Suzuki H, Moy RL, Kolodney MS. Detergent effects of sodium deoxycholate are a major feature of an injectable phosphatidylcholine formulation used for localized fat dissolution. *Dermatol Surg* 2004;30:1001-8.
13. Lennon C. Skin deep: is this the end for cellulite? Some doctors say, 'fat chance.' *New York Times*. May 19, 2005; Health section:3.
14. The Saturday Early Morning Show. Burn fat away with an injection? Available from: URL:<http://www.cbsnews.com/stories/>

- 2002/11/27/earlyshow/saturday/main531099.shtml. Accessed November 30, 2002.
15. The American Society for Aesthetic Plastic Surgery. Fat-melting fad: too good to be true? Available from: URL:<http://www.surgery.org/press/news-release.php?iid=387>. Accessed November 5, 2004.
 16. Matarasso A, Pfeifer TM. Mesotherapy for body contouring. *Plast Reconstr Surg* 2005;115:1420-4.
 17. Intravenous Fungizone (amphotericin B for injection) [package insert]. New York: Bristol-Myers Squibb; 2004.
 18. Lipostabil [package insert]. Frankfurt: Aventis Pharma; 2003.
 19. Hammad MA, Muller BW. Increasing drug solubility by means of bile salt-phosphatidylcholine-based mixed micelles. *Eur J Pharm Biopharm* 1998;46:361-7.
 20. Alkan-Onyuksel H, Ramakrishnan S, Chai HB, Pezzuto JM. A mixed micellar formulation suitable for the parenteral administration of taxol. *Pharm Res* 1994;11:206-12.
 21. Banerjee P, Joo JB, Buse JT, Dawson G. Differential solubilization of lipids along with membrane proteins by different classes of detergents. *Chem Phys Lipids* 1995;77:65-78.
 22. Almgren M. Mixed micelles and other structures in the solubilization of bilayer lipid membranes by surfactants. *Biochim Biophys Acta* 2000;1508:146-63.